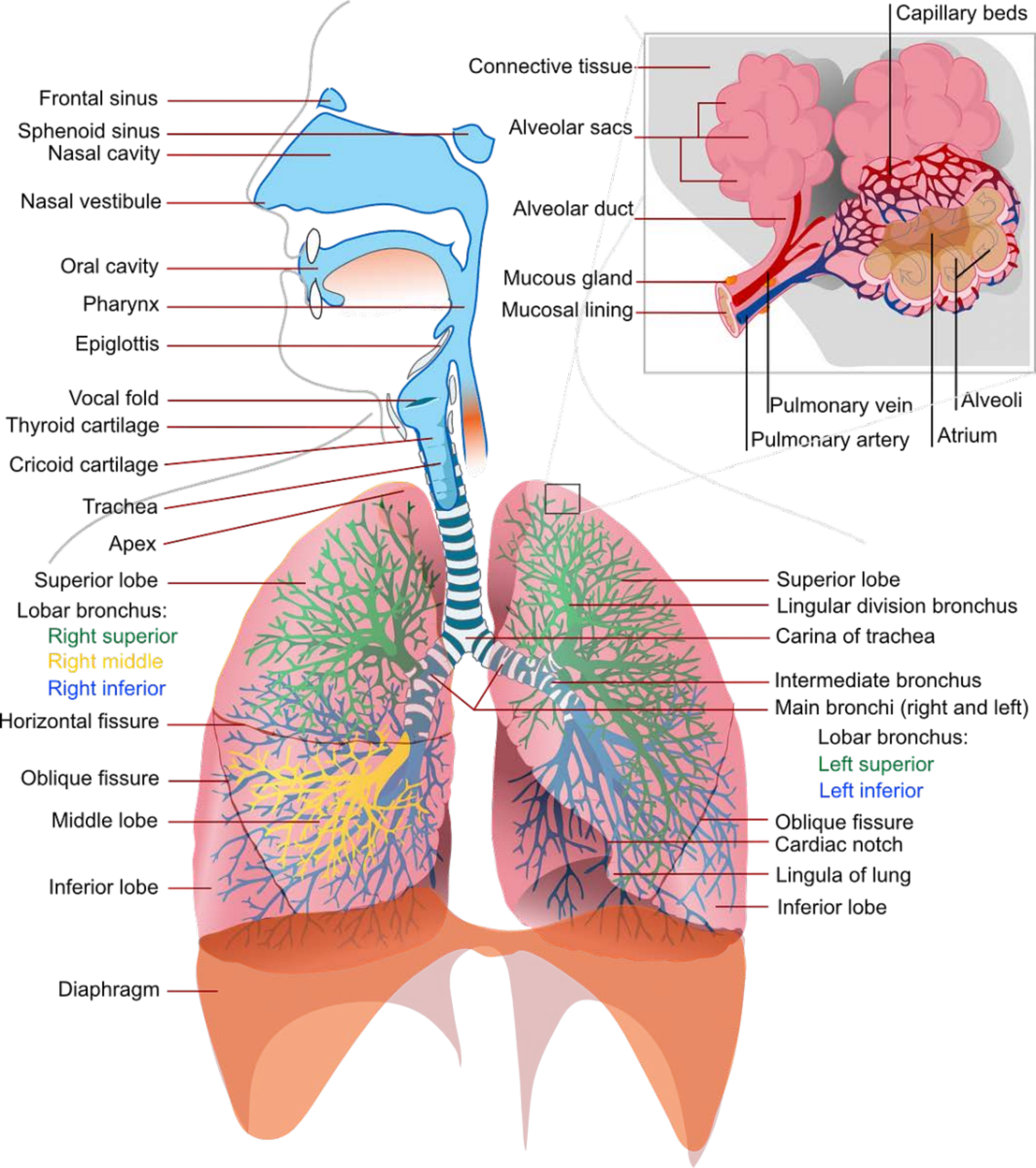
Frontal sinus
Sphenoid sinus
Nasal cavity
Nasal vestibule
Oral cavity
Pharynx
Epiglottis
Vocal fold
Thyroid cartilage
Cricoid cartilage
Trachea
Apex
Superior lobe
Lobar bronchus:
Right superior
Right middle
Right inferior
Horizontal fissure
Oblique fissure
Middle lobe
Inferior lobe
Diaphragm
Connective tissue
Alveolar sacs
Alveolar duct
Mucous gland
Mucosal lining
Capillary beds
Pulmonary vein
Pulmonary artery
Alveoli
Atrium
Superior lobe
Lingular division bronchus
Carina of trachea
Intermediate bronchus
Main bronchi (right and left)
Lobar bronchus:
Left superior
Left inferior
Oblique fissure
Cardiac notch
Lingula of lung
Inferior lobe