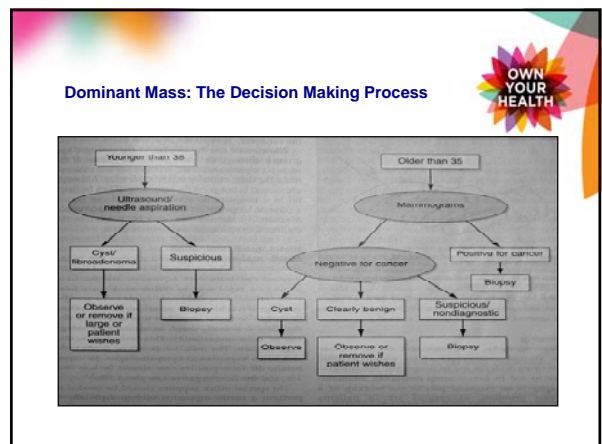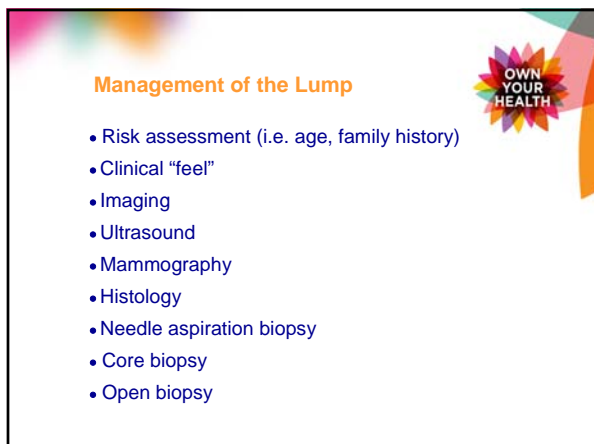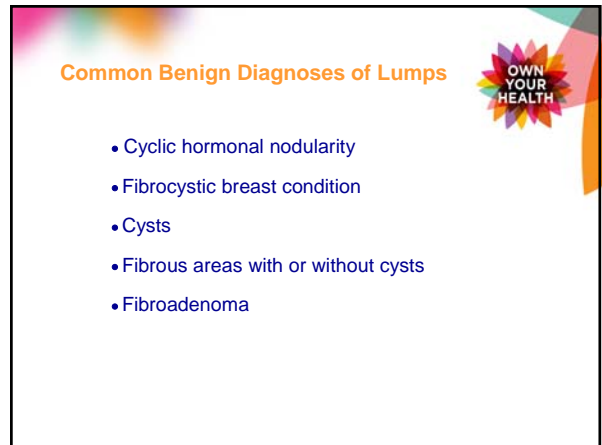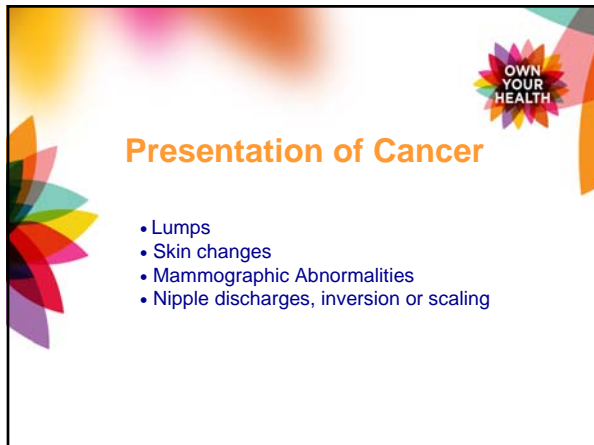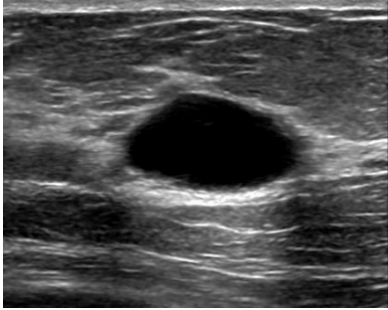


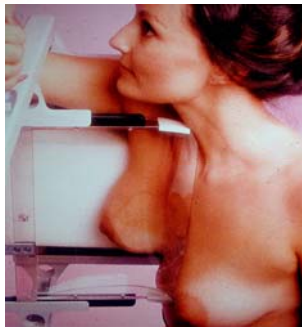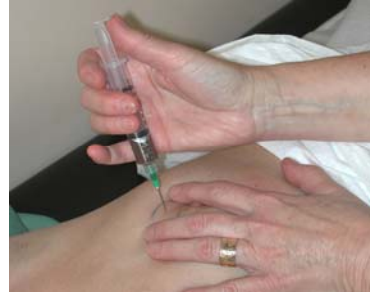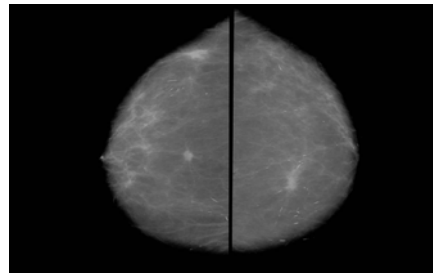
### Ultrasound of Cyst



### Needle Aspiration or Biopsy



### Abnormal Screen

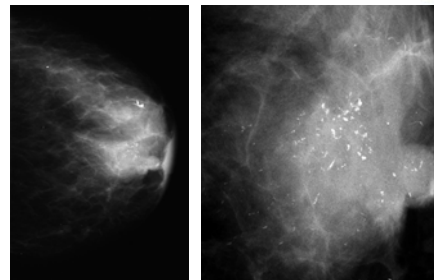


### Mammographic Abnormality (Screening)

- Surgeons rely on advice from radiologist
- Options depend on degree of suspicion of malignancy and mammographic characteristics
- May need:
  - Magnification View
  - Ultrasound Biopsy



### Magnification Views



## Biopsy Options for Mammographic Abnormality

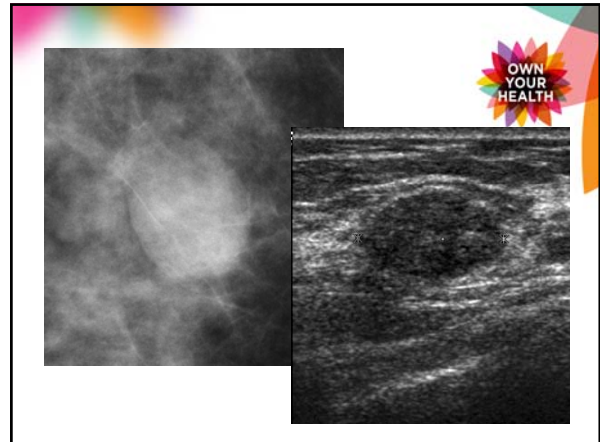


Visible on Ultrasound:

- Needle aspiration under US
- Core biopsy under US
- Fine wire biopsy with US localization

Visible only on Mammogram:

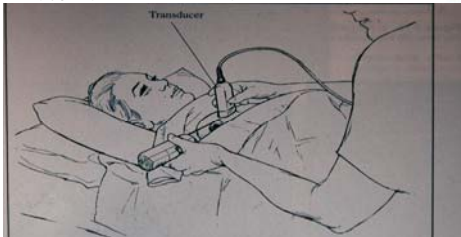
- Stereotactic core biopsy
- Fine wire localization biopsy



## Biopsy Under Ultrasound



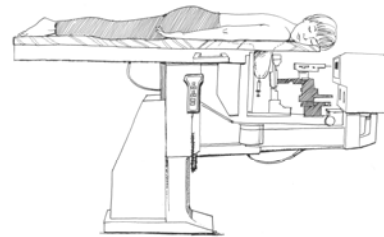
The patient is positioned comfortably in the supine position.  
The biopsy gun is positioned so that the needle parallels the chest wall.



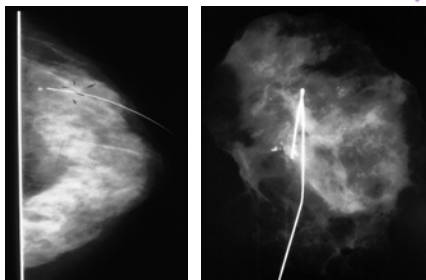
## Stereotactic Core Biopsy



Stereotactic Biopsy Table



## Fine Wire Localization Biopsy



## Nipple Discharge and Cancer

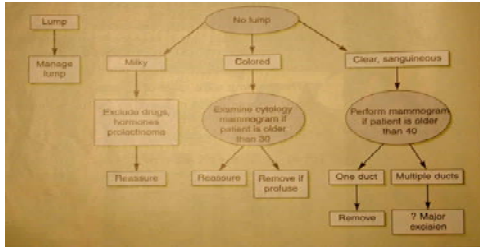


Nipple discharge can occasionally be a presenting symptom of cancer.

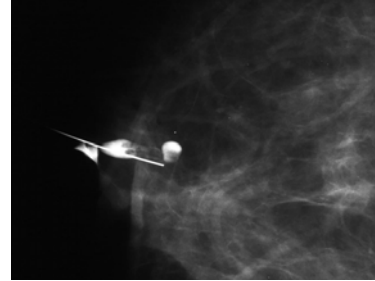
Alerts:

- Clear (like water)
- Bloody/yellow, profuse, spontaneous and from one duct
- Post menopausal
- Associated mass

## Nipple Discharge: Making a Diagnosis



## Intraductal Mass

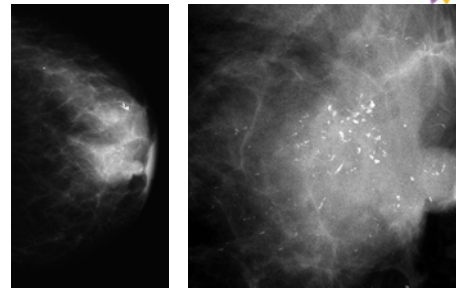


## Types of Breast Cancer



- In situ
  - lobular
  - ductal
- Invasive -ductal
  - lobular
  - other i.e. Sarcoma (<1%)
    - Lymphoma
    - Carcinosarcoma

## Ductal Carcinoma in situ



## Natural History of DCIS Seer Data 1978-89



	Death due 5yr	Breast ca 10yr	All other causes e.g. cardiac
1978-83	1.5%	3.4%	3.4%
1984-89	0.7%	1.9%	1.9%

## Surgery For DCIS



### PARTIAL MASTECTOMY

- Size less 5 cm
- Able to tolerate radiation

### TOTAL MASTECTOMY

- Size greater than 5cm
- Multifocal
- Patient choice

## Surgery For Invasive Breast Cancer



- Fine wire guided partial mastectomy
- Partial mastectomy
- Total mastectomy
- Axillary dissection
- Sentinel lymph node biopsy
- Reconstructive options

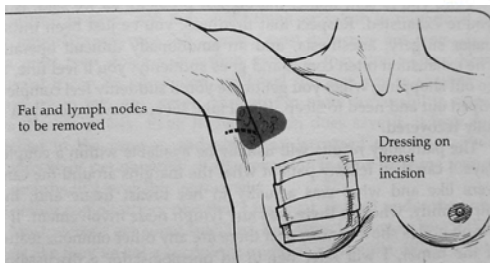
## Mastectomy vs. Breast Conservation



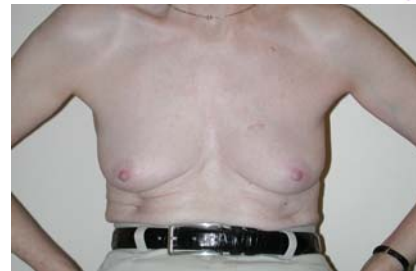### PARTIAL MASTECTOMY

- Patient preference
- Tumor size (less than 5 cm) and location favorable
- Unifocal tumor
- Ability to tolerate anesthetic and radiation

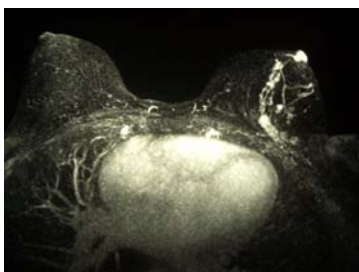
## Partial Mastectomy



## Partial Mastectomy



## MRI Cancer



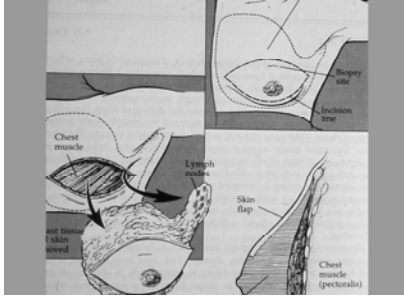
## Mastectomy vs. Breast Conservation



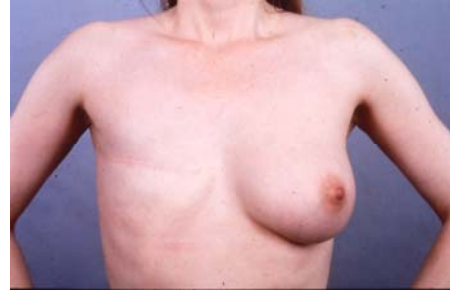### MASTECTOMY

- Patient preference
- Multifocal tumor
- Large tumor (larger than 5 cm)
- Inability to tolerate radiation

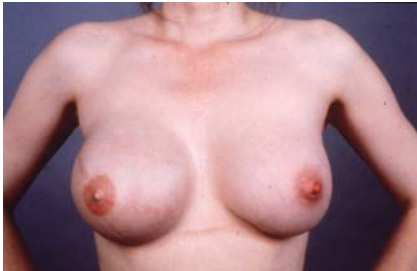## Mastectomy



## Mastectomy



## Mastectomy With Reconstruction



## Axillary Staging



Nodal status is greatest risk predictor

- Axillary dissection is indicated for invasive cancer

Sentinel node biopsy is becoming a "new standard" to avoid removal of negative nodes

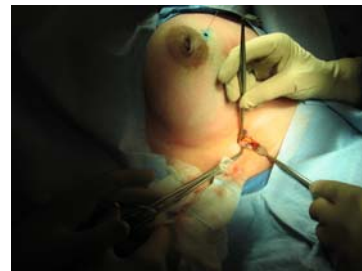## Axillary Staging



Sentinel node biopsy is done to stage the axilla but avoids unnecessary removal of lymph nodes

The breast is injected with a radionuclide and a blue dye which travels to the first draining lymph nodes (or nodes) and only those lymph nodes are removed and tested

## Sentinel Node Biopsy



## Contraindications For SLNB



- No breast available
- Clinically or pathologically positive nodes
- pregnancy
- ? tumor > 5 cm

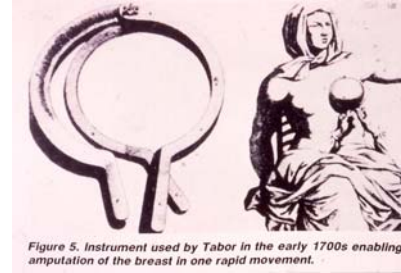


Figure 5. Instrument used by Tabor in the early 1700s enabling amputation of the breast in one rapid movement.



## Pathology Considerations in Invasive Breast Cancer



- Size
- LVI
- Grade
- Receptors ER, PR
- HER 2 (25% of cancers express)
- Nodal involvement - number, size extranodal extension

## Indications For Radiation



- Post lumpectomy for DCIS or invasive cancer
- Post mastectomy for high risk patients (e.g. Nodes positive, margins positive)
- Recurrent or metastatic disease

## Adjuvant Chemotherapy



Basis for recommendations for adjuvant chemotherapy		
Lowest risk (10% risk of recurrence after 10 years without therapy)	Moderate risk (10-20% risk of recurrence after 10 years)	High risk (more than 20% risk of recurrence after 10 years)
<b>All of:</b>	<b>All of:</b>	<b>Any one of:</b>
Tumor less than 1 cm plus no cancer in nodes plus no invasion into lymphatic or blood vessels of the Breast	Tumor 1-2 cm and grade 1 or 2 plus no cancer in nodes plus no invasion into lymphatic or blood vessels of the breast	Tumor more than 2 cm, or more than 1 cm and grade 3 and/or nodes contain cancer and/or invasion of lymphatic or blood vessels in the breast.
<b>Treatment:</b> No adjuvant chemotherapy; consider hormonal treatment if ER or PR positive*	<b>Treatment:</b> Hormone treatment if ER or PR positive* Chemotherapy if ER negative Age less than 35 HER2 Over expression	<b>Treatment:</b> Adjuvant chemotherapy, plus hormone therapy if ER or PR positive* Intensive adjuvant chemotherapy, plus hormone therapy if ER or PR positive*

\*ER = estrogen receptor, PR = progesterone receptor

## Hormonal Therapy



Recommendations For Postmenopausal Women			
Lowest risk	Moderate risk	High risk	Extreme risk
Adjuvant hormone therapy may be nil <b>Or</b> Letrozole x 3-5yr Tamoxifen x 5yr <b>Or</b> Anastrozole x 5yr <b>Or</b> Tam x 2-3yr followed by Exemstane x 2-3yr	Adjuvant hormone therapy with Tamoxifen x 5yr with consideration <b>Or</b> Anastrozole x 5yr <b>Or</b> Tam x 2-3yr followed by Exemstane x 2-3yr	Adjuvant chemo + Adjuvant hormone therapy with Anastrozole x 5yr <b>Or</b> Tam x 2-3yr followed by Exemstane x 2-3yr <b>Or</b> Tam x 5yr followed by Letrozole x 3-5yr	Adjuvant chemo + Adjuvant hormone therapy with Anastrozole x 5yr <b>Or</b> Tamoxifen x 2-3yr followed by Exemstane x 2-3yr <b>Or</b> Tam x 5yr followed by Letrozole x 3-5yr

OWN  
YOUR  
HEALTH

